

What is Axial Spondyloarthritis?

How does it apply to physiotherapists?

Claire Harris, Senior Physiotherapist,
London North West University Healthcare NHS Trust

Susan Gurden, Advanced Physiotherapy
Practitioner in Rheumatology,
Aneurin Bevan Health Board, Wales

Dr Jane Martindale, Clinical Specialist Physiotherapist,
Wrightington, Wigan and Leigh NHS Foundation Trust

Claire Jeffries, Physiotherapy Clinical Specialist
in Hydrotherapy and Rheumatology,
Solent NHS Trust, Portsmouth

Contents

<u>Introduction</u>	3
<u>What is axial SpA?</u>	5
<u>Classification criteria for axial SpA</u>	6
<u>Axial SpA: spectrum of disease</u>	8
<u>Identifying inflammatory back pain and managing axial SpA</u>	10
<u>Assess your knowledge of axial SpA</u>	13
<u>Glossary</u>	15
<u>Useful contacts and further information</u>	16
<u>Modules in this series</u>	16

Introduction

This module provides an overview of the epidemiology, symptoms and classification of axial spondyloarthritis (axSpA), and highlights the clinical features that you should look for to identify potential patients.

Inflammatory back pain (IBP) is one of the key symptoms of axial SpA. Information on IBP is available in module 1 of this series, *Differentiating Inflammatory and Mechanical Back Pain*.

Module objectives

After reading this module, you should:

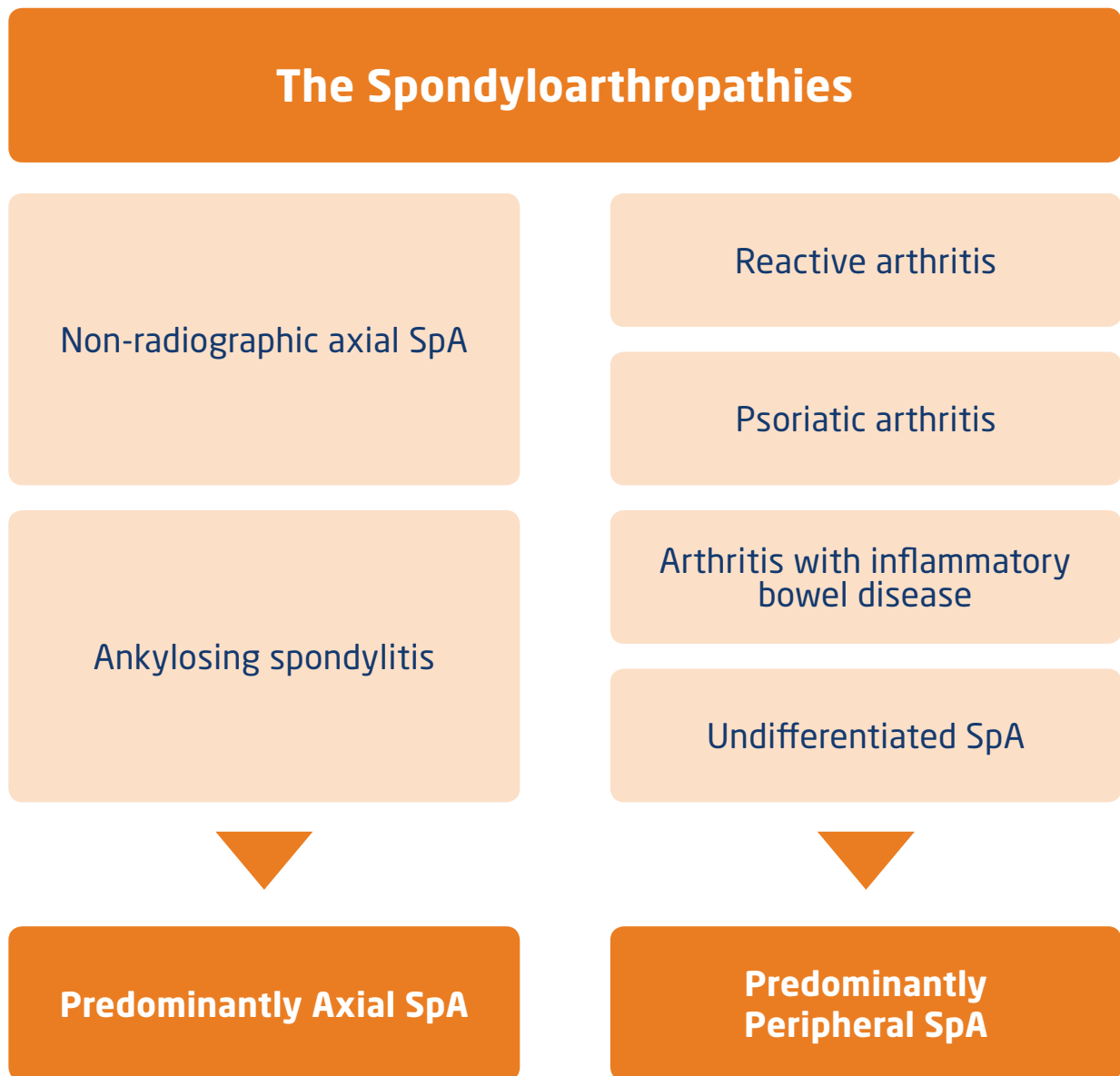
- Know the type of diseases classified as spondyloarthritis.
- Understand that axial SpA describes a spectrum of disease including non-radiographic axial SpA (nr-axSpA) and ankylosing spondylitis (AS)
- Be aware of criteria used to classify axial SpA and diagnose AS.
- Understand that axial SpA may follow a progressive course and the importance of early referral.

What is Spondyloarthritis (SpA)?

Spondyloarthropathies are a group of chronic inflammatory rheumatic diseases that share overlapping features such as sacroiliitis, enthesitis, extra-articular manifestations (e.g. acute anterior uveitis, psoriasis, and inflammatory bowel disease), HLA-B27 positivity and familial aggregation.^{1,2}

They can be divided into two main groups which describe the presenting symptoms (although these can overlap and one may progress to the other).

- Axial SpA (spine and sacroiliac joints).
- Peripheral SpA (peripheral joints).



What is axial SpA?

- Axial SpA describes a spectrum of types of chronic inflammatory arthritis involving the spine and/or sacroiliac joints.
- Axial SpA is a form of spondyloarthritis where the predominant symptom is often chronic IBP and where radiographic sacroiliitis may or may not be present.³
- Axial SpA may be diagnosed as either ankylosing spondylitis (AS) or non-radiographic axial SpA (nr-axSpA), depending on the presence of radiographic sacroiliitis.^{3,4}

Axial SpA

Non-radiographic axial SpA

Nr-axSpA is a form of axial SpA in which sacroiliac joint lesions are either not present on X-ray or do not meet the mNYC for AS. Lesions may, however, be present on MRI. These and/or other clinical criteria are used for the diagnosis of nr-axSpA⁵

Ankylosing spondylitis

AS is a form of axial SpA in which lesions of the sacroiliac joint meet the modified New York criteria (mNYC; see page 6) for AS and are visible on X-ray⁴

- Axial SpA may be associated with systemic inflammation and patients may have eye, skin and gut involvement.⁶ The disease may be characterised by inflammation of the sacroiliac joints, facet joints and spinal entheses. This results in back pain, fatigue, stiffness and may lead to ankylosis (joint fixation).⁷
- Bone damage (such as erosion and sclerosis) is irreversible and may be progressive; in the early stages, it is associated with vertebral osteoporosis and there is an increased risk of spinal fracture later in life.^{8,9}

Classification criteria for axial SpA

Axial SpA can be divided into three groups according to imaging-based criteria.

Non-radiographic axial SpA

In which sacroiliac joint lesions are either not present on X-ray or do not meet the mNYC, with the disease diagnosed through MRI and clinical criteria (see page 7)⁵

Earlier radiographic forms of AS

In which an X-ray confirms sacroiliitis but no spinal changes (as defined by the mNYC)³

Advanced radiographic forms of AS

In which an X-ray confirms both sacroiliitis (i.e. inflammation of the sacroiliac joint) and/or spinal changes (as defined by the mNYC)⁴

Modified New York Criteria for the diagnosis of AS⁴

A diagnosis of definite AS may be made if the radiographic criterion is present plus at least one clinical criterion.

Radiographic criteria:

- Sacroiliitis grade ≥ 2 bilaterally or sacroiliitis grade 3-4 unilaterally.

Clinical criteria:

- Low back pain and stiffness for >3 months which improves with exercise but is not relieved by rest.
- Limitation of motion of the lumbar spine in both the sagittal and frontal planes.
- Limitation of chest expansion relative to normal values corrected for age and sex.

ASAS classification criteria for axial SpA

The ASAS (Assessment of SpondyloArthritis international Society) criteria were developed to support assessment of those who do not fulfil the mNYC.

To meet the criteria, a patient must have either sacroiliitis on imaging plus at least one other feature listed below, or be HLA-B27 positive (a genetic marker strongly associated with SpA), plus have at least two other features.⁵

**In patients with chronic back pain (≥ 3 months)
who were < 45 years old at onset⁵**

**Sacroiliitis on imaging*
plus
 ≥ 1 SpA feature
(listed below)**

**HLA-B27
plus
 ≥ 2 other SpA features
(listed below)**

Sacroiliitis on Imaging*

Active (acute) inflammation on MRI highly suggestive of sacroiliitis associated with SpA or definite radiographic sacroiliitis according to mNYC

SpA features[†]

- IBP
- Arthritis
- Heel enthesitis
- Uveitis
- Dactylitis
- Psoriasis
- Crohn's disease/ulcerative colitis
- Good response to non-steroidal anti-inflammatory drugs (NSAIDs)
- Family history of SpA
- HLA-B27 positivity
- Elevated C-reactive protein (CRP)

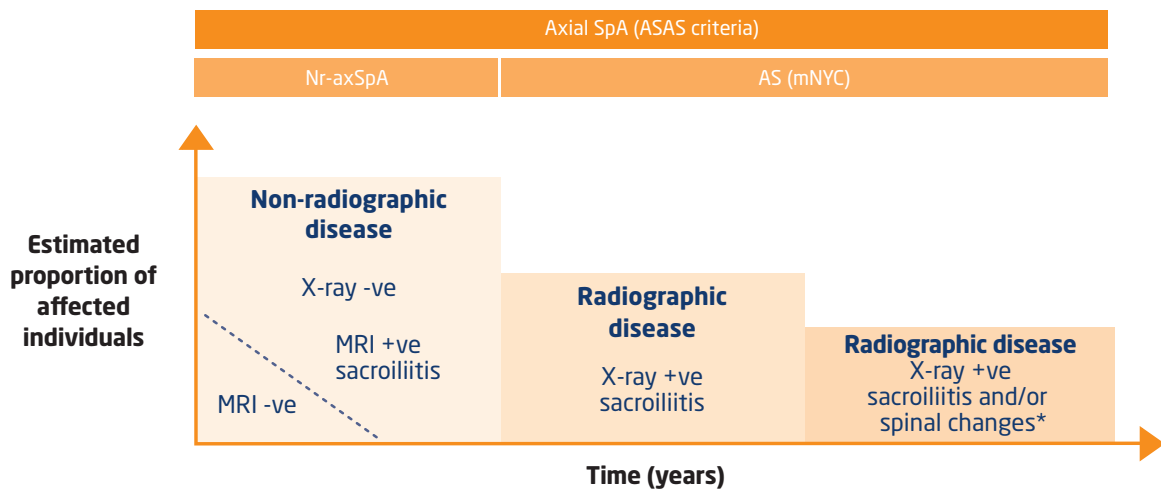
[†] More information on the clinical and extra-articular features of axial SpA can be found in module 3: Assessing the Signs, Symptoms and Clinical Manifestations of Axial SpA

Axial SpA: spectrum of disease

In many patients, the disease follows a progressive course (from left to right in the figure below). However, not all patients with nr-axSpA go on to develop AS.

Nr-axSpA progresses to AS at a rate of about 12% over 2 years.¹⁰

Spectrum of disease in patients with chronic back pain (≥ 3 months) aged < 45 years at onset¹¹



This figure is adapted from Isdale S, et al. *Rheumatology (Oxford)* 2013;52(12):2103-2105

The figure depicts the spectrum of disease in patients with axSpA. The severity of disease progresses with time in a proportion of patients and the sizes of the boxes are estimates of the proportion of patients in each tertile. The first tertile represents early non-radiographic disease, the second and third tertiles represent radiographic disease (AS) with the most severe end of the spectrum including spinal involvement (syndesmophyte formation, fusion or posterior element involvement).

*Radiographic evidence of spinal changes, including syndesmophytes^a, fusion or posterior element involvement. More information on these features of axial SpA can be found in module 3 of this series: Assessing the signs, symptoms and clinical manifestations of axial SpA

^a Bony growths originating inside a ligament, commonly seen in the ligaments of the spine

Non-radiographic axial SpA and AS

Early diagnosis of non-radiographic axial SpA and AS is essential for effective treatment

- Axial SpA is often mis-diagnosed or not diagnosed for several years after a patient first experiences symptoms. Early diagnosis is essential for optimal patient care.¹²
- It is often difficult to differentiate between different causes of back pain. Appropriate patient assessment is important for identifying features related to IBP (for more information on IBP, please refer to module 1).

If you suspect axial SpA, further investigation is required by a rheumatologist. You should initiate a referral to rheumatology via your local referral pathway.



Approximately 50% of nr-axSpA patients are female^{13,14,15}

However, AS generally affects more males than females^{16,17,18}

89% of patients with axial SpA (nr-axSpA and AS) have IBP⁵

Both nr-axSpA and AS patients suffer from a similar burden of disease¹⁹

Identifying inflammatory back pain and managing axial SpA

There are several key questions you can ask to determine if a patient's back pain is mechanical or inflammatory. The following is taken from the ASAS criteria for identifying inflammatory back pain:^{20*}

In patients with back pain of >3 months duration

- 1 Did your back pain start when you were aged younger than 40?
- 2 Did your back pain develop gradually?
- 3 Does your back pain improve with movement?
- 4 Do you find there is no improvement in your back pain when you rest?
- 5 Do you suffer from back pain at night which improves upon getting up?

If the answer is 'yes' to 4 or more of these questions, IBP requiring further investigation is usually indicated²⁰

Axial SpA is a serious debilitating disease which can lead to reduced function and progressive joint deformity. As well as identifying IBP, physiotherapists also play a key role in the on-going management of axial SpA:

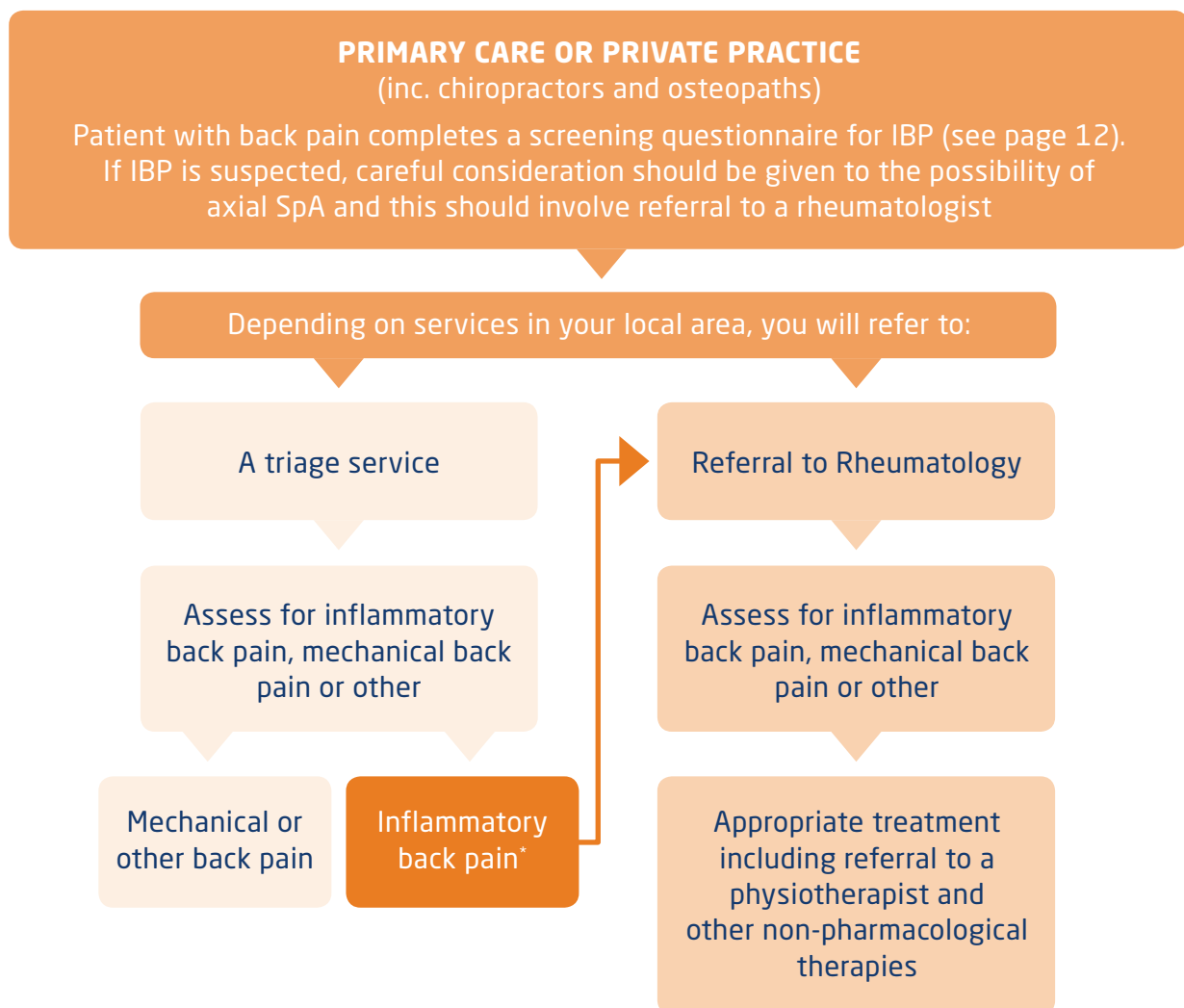
- Physiotherapy as a treatment for axial SpA aims to maintain or improve function.
- Physiotherapists play a key role in facilitating pain management, improving physical ability and providing education on self-management.

As well as the physical burden faced by individual patients, back pain causes reduced quality of life and is a major cause of workers' absenteeism.²¹ Appropriate management of axial SpA can help improve patients' quality of life and improve socio-economic outcomes.

* More information on IBP is available in module 1 of this series, *Distinguishing Inflammatory and Mechanical Back Pain*

Supporting early diagnosis of axial SpA by identifying inflammatory back pain

- The delay between the appearance of first symptoms and diagnosis of axial SpA is typically ~5-10 years,²² meaning that an opportunity for early treatment can be missed.
- Physiotherapists can play a key role in the early identification of patients with IBP, a key symptom of axial SpA (see pathway example below).



*If the diagnosis is unclear, a referral to a rheumatologist, directly or via your local referral pathway, should be completed.

- Collaborative care between rheumatologists, physiotherapists and other specialists is crucial to achieving effective care for axial SpA patients. The optimal management of patients with axial SpA requires a combination of non-pharmacological and pharmacological treatment modalities, therefore specialists from different departments should work together to achieve axial SpA patients' treatment goals.²³

The inflammatory back pain questionnaire

The Assessment of SpondyloArthritis International Society (ASAS) expert criteria, is a simple and useful tool which you can use to assess your patient's pain.⁷

The criteria comprises the following questions:

Have you suffered back pain for more than 3 months?

If yes:

Did your back pain start when you were aged 40 or under?

Did your back pain develop gradually?

Did your back pain improve with exercise?

Do you find there is no improvement in your back pain when you rest?

Do you suffer from back pain at night which improves upon getting up?

The criteria are fulfilled if at least four out of five parameters are present. In this case, please refer the patient to a rheumatologist for further investigation as the pain could be due to a form of inflammatory arthritis.

Assess your knowledge of axial SpA

Please complete the multiple choice questions below.

1. Axial SpA is a spectrum of chronic inflammatory arthritis involving (choose one answer)
 - a. The spine and/or sacroiliac joints
 - b. The spine and/or skull
 - c. The arms and legs

2. AS is a form of axial SpA distinguished by (choose one answer)
 - a. An X-ray positive for sacroiliitis according to the modified New York criteria
 - b. An MRI negative for sacroiliitis according to the ASAS criteria
 - c. An X-ray negative for sacroiliitis according to the modified New York criteria

3. The ASAS criteria for the classification of axial SpA apply to patients with (choose one answer)
 - a. Acute back pain who were <45 years old at onset
 - b. Chronic back pain (>3 months) who were <45 years old at onset
 - c. Acute back pain who were >45 years old at onset
 - d. Chronic back pain (>3 months) who were >45 years old at onset

4. Which of the following patients could be classified as having axial SpA according to the ASAS classification criteria for axial SpA? (tick all that apply)
 - a. 35 year old female with an MRI positive for sacroiliitis and a history of uveitis
 - b. A 29 year old male with Crohn's disease and psoriasis, who is HLA-B27 negative
 - c. A 40 year old male who is HLA-B27 positive and has enthesitis of the patella
 - d. A 46 year old male who is HLA-B27 positive, has elevated CRP and who has had IBP for 6 years

5. Features of axial SpA included within the ASAS criteria for axial SpA are (tick all that apply)
- a. Inflammatory back pain
 - b. Mechanical back pain
 - c. Psoriasis
 - d. Elevated C-reactive protein (CRP)
 - e. Elevated erythrocyte sedimentation rate (ESR)
6. Which of the following statements relating to the symptoms of IBP are true? (tick all that apply)
- a. Symptoms are often improved with movement and exercise
 - b. There is usually an improvement of the pain with rest
 - c. The pain is usually insidious in onset
 - d. Symptoms often improve at night

Answers are provided on the back page.

Personal reflection and new key learning points

Personal actions

Glossary

Axial spondyloarthritis (axSpA)

A form of spondyloarthritis, composed of both non-radiographic axial SpA and AS, and where radiographic sacroiliitis may or may not be present.

Crohn's disease

A chronic inflammatory disease of the intestines, especially the colon and ileum, associated with ulcers and fistulae.

Dactylitis

An inflammation of the fingers and/or toes with or without pain. Dactylitic fingers and toes are often referred to as 'sausage digits'.

Enthesitis

Inflammation of the entheses, the points at which a tendon or ligament or muscle inserts into bone.

Human Leukocyte Antigen HLA-B27

A class I surface antigen encoded by the B complex in the major histocompatibility complex on chromosome 6. HLA-B27 positivity is associated with spondyloarthritis.

Psoriasis

A chronic, inflammatory disease characterised by scaly skin lesions, which can be in the form of patches, papules, or plaques.

Sacroiliitis

Originally used to describe bony changes in the sacroiliac joint on plain X-ray, the term is also used to describe inflammation of the sacroiliac joint seen on MRI.

Syndesmophytes

Bony growths originating inside a ligament, commonly seen in the ligaments of the spine.

Ulcerative colitis

An inflammatory bowel disease characterized by inflammation with ulcer formation in the lining of colon (large intestine).

Uveitis

Inflammation of the uvea, the middle layer of the eye. The most common type of uveitis is an inflammation of the iris called anterior uveitis (iritis).

Useful contacts and further information

British Health Professionals in Rheumatology (BHPR)
www.rheumatology.org.uk

NASS website

www.nass.co.uk/managing-my-as/exercise/physiotherapy/

The Chartered Society of Physiotherapy (CSP)
www.csp.org.uk

AStretch
www.astretch.co.uk

ASAS
www.asas-group.org

Modules in this series

Module 1: Differentiating Inflammatory and Mechanical Back Pain

A comparison of the features of inflammatory and mechanical back pain and a detailed outline of the assessment and diagnosis process for inflammatory back pain.

Module 2: What is Axial Spondyloarthritis?

An overview of the epidemiology, symptoms and classification of axSpA, and the clinical features that identify potential patients.

Module 3: Assessing the Signs, Symptoms and Clinical Manifestations of Axial SpA

Information on the key clinical features and extra-articular manifestations of non-radiographic axial SpA and AS and how to identify these.

Module 4: Treatment of Axial Spondyloarthritis

Non-pharmacological and pharmacological management of patients with axSpA.

References

1. Khan MA, et al. *Ann Intern Med*. 2002;136:896-907. 2. van der Heijde D, et al. *Arthritis Rheum* 2006;54:2136-2146. 3. Rudwaleit M, et al. *Arthritis Rheum* 2005;52:1000-1008. 4. van der Linden S, et al. *Arthritis Rheum* 1984;27:361-368. 5. Rudwaleit M, et al. *Ann Rheum Dis* 2009;68:777-783. 6. Brophy S, et al. *J Rheumatol* 2001;28:2667-2673. 7. Sieper J, et al. *Ann Rheum Dis* 2009;68(Suppl II):iii1-ii44. 8. Donnelly S, et al. *Ann Rheum Dis* 1994;53:117-121. 9. Machado P, et al. *Ann Rheum Dis* 2010;64:1465-1470. 10. Poddubnyy D, et al. *Curr Opin Rheumatol* 2012;24:363-369. 11. Isdale A, et al. *Rheumatology (Oxford)*. 2013;52(12):2103-5. 12. van der Heijde D, et al. *ACR* 2012;2208. 13. Sieper J, et al. *Ann Rheum Dis* 2012;0:1-8. 14. Rudwaleit M, et al. *Arthritis Rheum* 2009;60:717-727. 15. Haibel H, et al. *Arthritis Rheum* 2008;58:1981-1991. 16. Davis JC, et al. *Arthritis Rheum* 2003;48:3230-3236. 17. Inman R, et al. *Arthritis Rheum* 2008;58:3402-3412. 18. van der Heijde D, et al. *Arthritis Rheum* 2005;52:582-591. 19. Sieper J, et al. *ACR* 2012;1361. 20. Sieper J, et al. *Ann Rheum Disease* 2009;68:784-788. 21. van Tulder M, et al. *Eur Spine J* 2006;15(Suppl.2):S169-S191. 22. Brandt HC, et al. *Ann Rheum Dis* 2007;66:1479-1484. 23. Braun J, et al. *Ann Rheum Dis* 2011;70:896-904.

Answers to questions

1: a; 2: a; 3: b; 4: a,d; 5: a,c,d; 6: a,c